



Retroperitoneal laparoscopic cool-tip radiofrequency ablation of adrenocortical adenoma with Cushing syndrome

LINFANG YAO, SHIWEI ZHANG, XIAOZHI ZHAO, RONG YANG, HONGQIAN GUO
Department of Urology, Nanjing Drum Tower Hospital, Nanjing, 210008, China



Introduction

- Total adrenalectomy may result in permanent hormonal deficiency. Patients treated with adrenal-sparing surgery may have much more improved quality of life. The laparoscopic adrenal-sparing approach could reduce the blood loss and hasten hospital stay.
- Recent technologic advances have brought kinds of new minimally invasive, organ-sparing procedures. Radiofrequency ablation (RFA) is a safe and efficacious treatment modality for the ablation of neoplasms in a variety of tissues. Some reports have also shown a good therapeutic response with RFA on adrenal cancer and adrenal metastases.
- However, few reports have mentioned the clinical utility of RFA on functioning adrenal tumors. Usually an adrenal gland tumor is found in the most common type of endogenous Cushing syndrome. We performed retroperitoneoscopic-guided cool-tip radiofrequency ablation(RCRFA) for treating adrenocortical adenoma with Cushing syndrome in order to reduce patient morbidity and hasten postoperative recovery while preserving normal adrenal tissue.

Objectives

To evaluate the feasibility, safety, and therapeutic effects of retroperitoneoscopic-guided cool-tip radiofrequency ablation (RCRFA) used for the treatment of adrenocortical adenoma with Cushing syndrome.

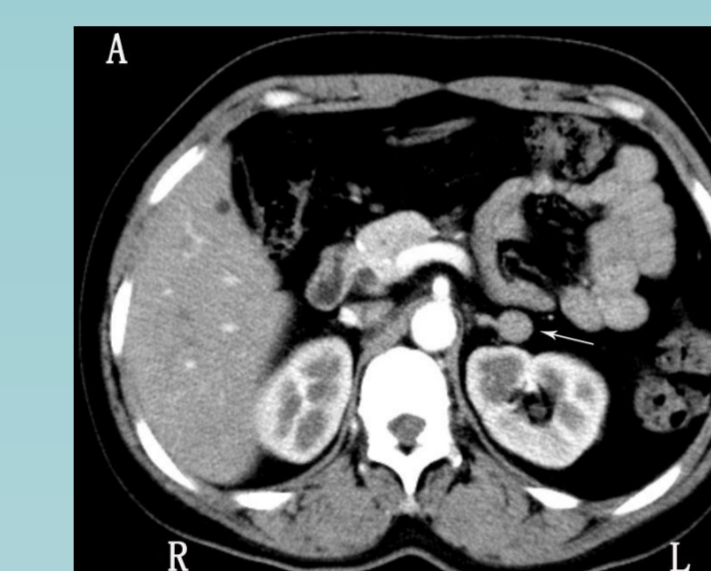
Methods

- From May 2006 to May 2009, 12 female patients with adrenocortical adenoma and Cushing syndrome underwent RCRFA.
- Ten tumors were in the left adrenal gland and two tumors were in the right, with a mean tumor size of 2.8 ± 0.5 cm (range 2.0 to 3.5).
- Technical success was defined as disappearance of tumor enhancement on contrast-enhanced computed tomography imaging acquired within 4 weeks after RCRFA.
- Clinical success was defined as improvement in serum cortisol and adrenocorticotrophic hormone (ACTH) values and symptoms at the end of follow-up.

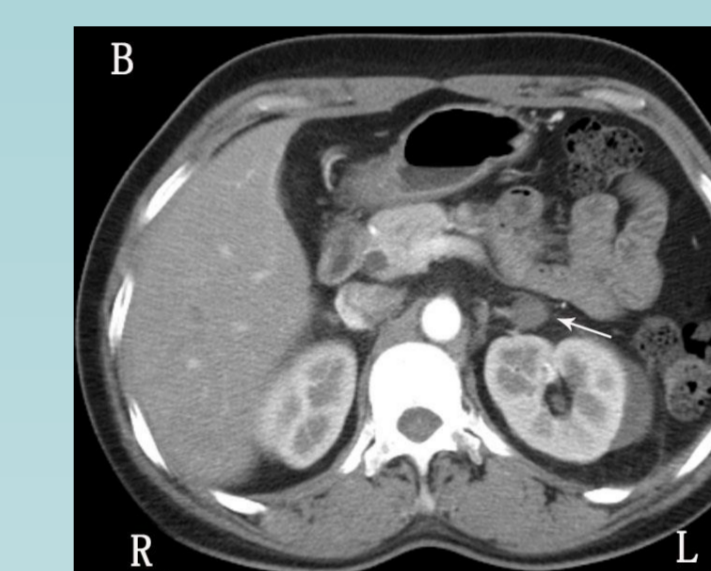
Results

- Tumor enhancement disappeared after initial RCRFA in all patients (technical success rate 100%) one month later.
- Both the serum cortisol and ACTH levels returned to normal and the symptoms related to Cushing syndrome had disappeared.
- Every patient was followed up for more than 6 years (mean 85.2 ± 11.2 months).
- There was no evidence of residual or recurrent lesion postoperatively.
- All tumors had shrunk (1.5 ± 0.6 cm) at the end of the study.
- No major complications occurred related to the procedures

Results



(A) Contrast-enhanced CT scan obtained before RFA showing well-enhanced adrenal mass measuring 2.2 cm in maximal diameter (arrow).



(B) Contrast-enhanced CT image obtained 1 month after RFA of the lesion shows complete ablation of the left adrenal gland lesion (arrow).

FIG. 1. A 43-year-old woman with left adrenal gland mass.

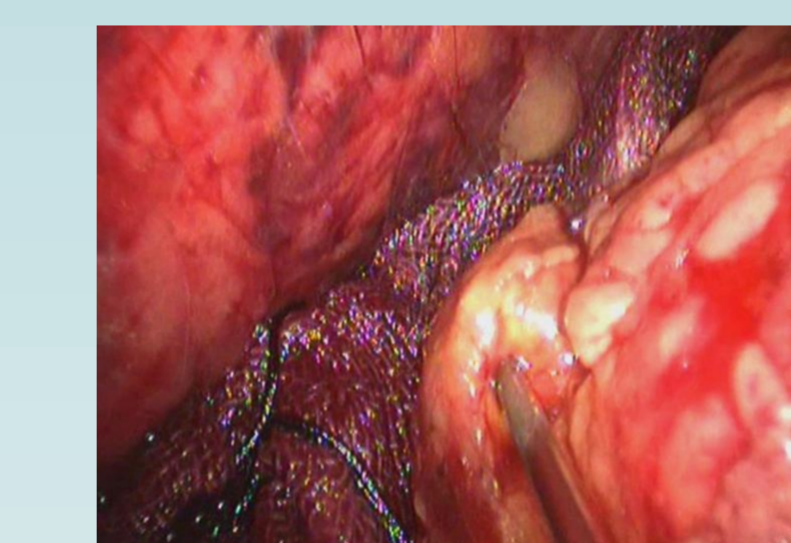


FIG. 2.

FIG. 2. Retroperitoneoscopic-guided biopsy using Tru-Core I 22 G biopsy needle for adrenocortical mass.

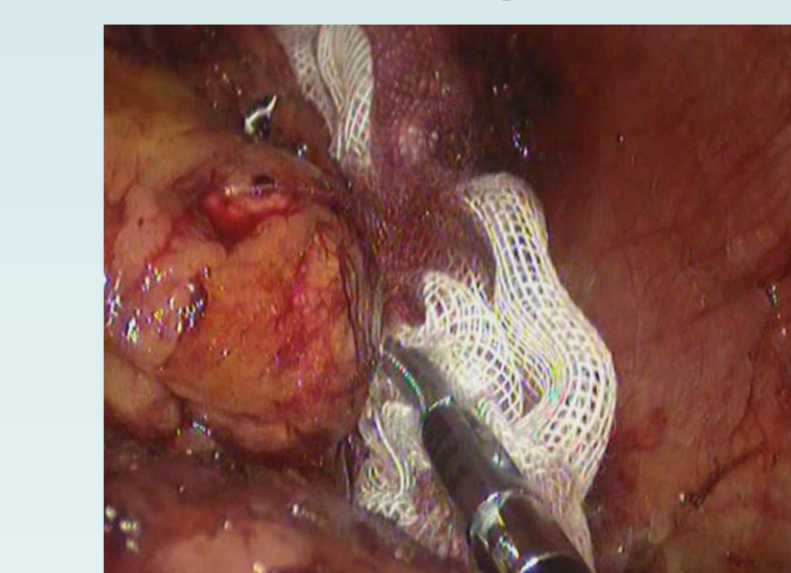
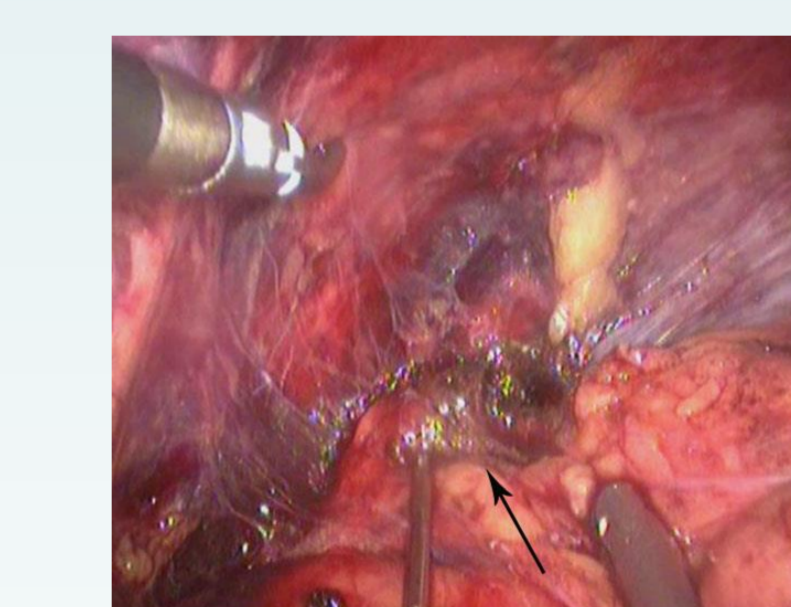
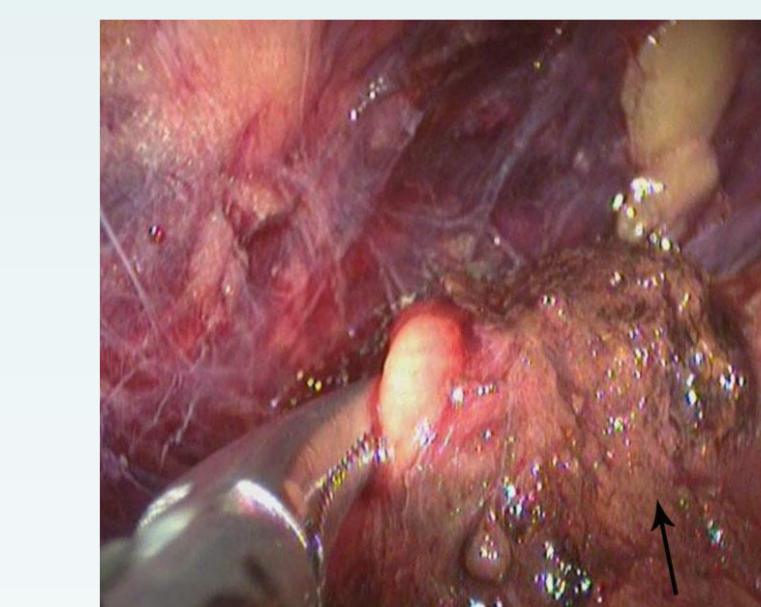


FIG. 3.

FIG. 3. Avoiding accidental damage before radiofrequency energy was applied by placing the sterile carbasus over the Venae Cavae in case the tumor was in the right adrenal gland.



(A) RFA of the left adrenal gland lesion (arrow) was started.



(B) RFA of the left adrenal gland lesion (arrow) was complete.

FIG. 4. Retroperitoneoscopic-guided cool-tip radiofrequency ablation for adrenocortical mass.

Conclusions

Using RCRFA for adrenocortical adenoma with Cushing syndrome is a feasible, safe, and promising treatment method in selected patients.